

ROLE OF TRAUMATIC SEATBELT FAT STRANDING IN AUTOMOTIVE CRASH INJURY ANALYSIS

Chandrashekhar K. Thorbole

Thorbole Simulation Technologies LLC
United States

Prashant Naik

SKN Medical College, Radiology Department
India

Paper Number 19-0137

ABSTRACT

The seatbelt is a primary and the most important passive safety device protecting occupants in all crash modes. The belt must work in harmony with other passive safety devices such as the frontal airbag, knee bolster and the seat to increase the level of occupant protection in a head-on crash. Failure of any component to restrain the occupant effectively in conjunction with the seatbelt can produce adverse occupant kinematics. Occupant submarining in a frontal crash is an occurrence when the belt moves from the desired stronger skeletal site and loads undesired anatomical location during the forward excursion of the occupant. The focal loading of the abdomen and ribs by the seatbelt produces abdominal and thorax severe injuries.

Subcutaneous fat appears typically darker on the radiographic film with an appropriate window. The focal loading from the seatbelt on the body tends to increase the density of the fat along the course of the seatbelt routing. The increase in the density of fat rises its attenuation and makes the fat appear lighter/whiter on the film. The change in the density, due to traumatic seatbelt loading, can be used in conjunction with other medical and physical evidence to demonstrate the occurrence of submarining. This type of analysis is also useful for the medical provider to take appropriate actions when the trauma patient first appears in the emergency department.

The purpose of this study is twofold: (1) to demonstrate the submarining detection techniques and methodologies using the NHTSA crash-test instrumentation data; and (2) to present real-world crashes as evidence of occupant submarining using fat-stranding analysis in conjunction with other medical and physical evidence.

INTRODUCTION

Automotive passive safety performance in a frontal crash scenario depends on how well the seatbelt and other safety components work together to dissipate occupants kinetic energy while exerting a load on the stronger osseous anatomy[1,2,3,4,5]. However, if the seatbelt transfers load on the body regions such as the abdomen and the ribs, it changes the injury pattern and its severity[6,7]. Occupant submarining in a frontal crash involves slipping of properly placed lap belt from the iliac spine on to the abdomen[8,9]. The traumatic contact between the lap belt and the abdomen as a result of submarining produce direct compressive and shear forces tangential to the abdominal wall exerted by the belt. This force application pattern is evident from the crash testings belt dynamics on the abdomen at the instant of submarining.

The abdominal wall anatomy is composed of skin, superficial subcutaneous fat (Camper fascia), Scarpa fascia and muscle layers separated by their fascia's. The subcutaneous fat, a low dense substance appears darker on the scans due to decreased attenuation. However, with the application of compressive and shear loading on the subcutaneous fat can increase its density in the load application regions. The increase in the density compared to the surrounding local area cause pockets of increased attenuation that appears lighter on the CT scans. Figure 1 shows an example of increased fat density causing increased attenuation making the pockets of fat in the subcutaneous tissue to appear lighter on the CT scan. Figure 2 shows the typical appearance of the subcutaneous fat without any fat stranding.

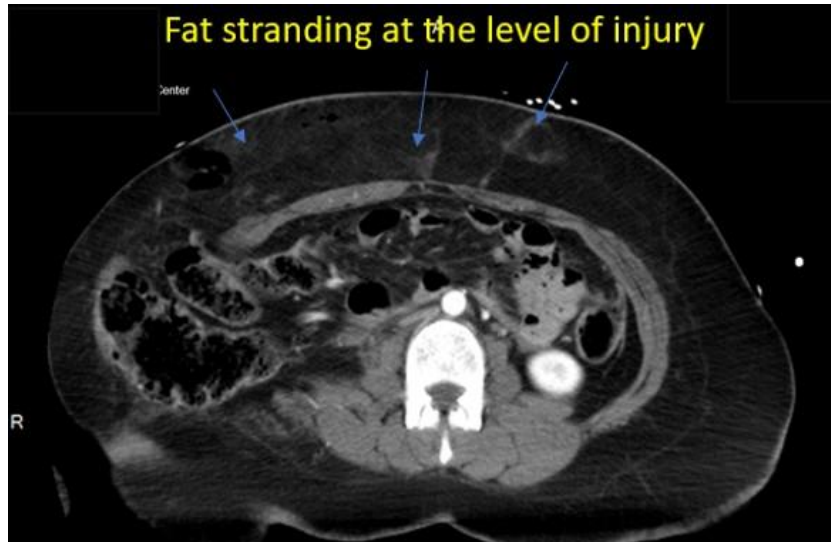

Figure 1. Subcutaneous fat stranding at the level of seatbelt injury.

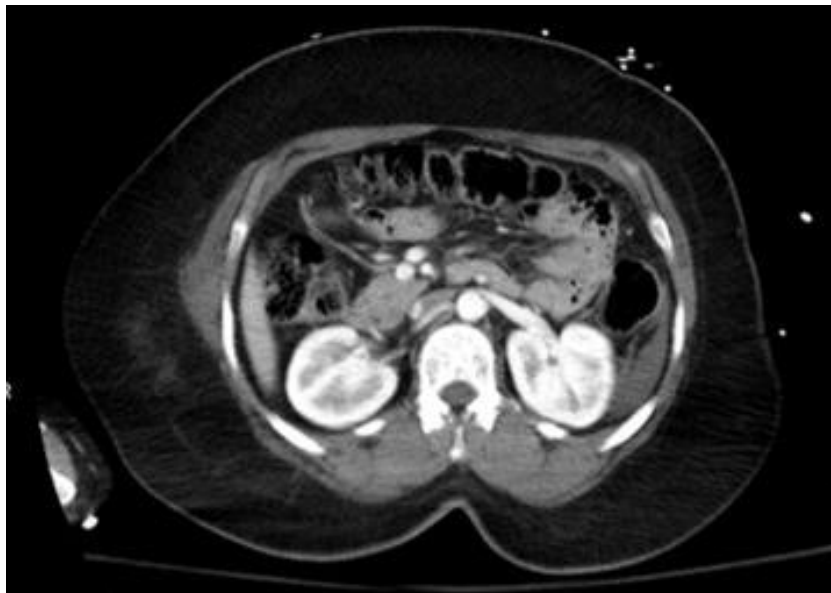

Figure 2. Subcutaneous fat appearance on the CT scan in absence of traumatic fat stranding.

Submarining detection in itself is separate research as submarining prevention. Detection of submarining is mainly challenging due to the use of mechanical crash dummies used for the design and performance evaluation process. The Hybrid III 5th is sensitive to submarining compared to the 50th and the 95th crash dummies[10,11] making it a relative better choice to detect the submarining.

The seatbelt load profile, A.S.I.S load cell output, and the film analysis can be effectively used to detect the occupant submarining or risk of submarining in a frontal crash scenario. The primary objective of this paper is to demonstrate the submarining detection method using standard regulatory test data and to discuss the application of fat-stranding analysis to explain submarining in real-world crashes and factors dictating the outcome.

METHODOLOGY

NHTSA crash-test database [12] is searched for the frontal tests with 5th percentile ATD in the rear seat. Two rigid barrier tests were selected to compare the data and to demonstrate the submarining detection techniques using film and the seatbelt data. Vehicles in both tests belonged to the same class.

Test-1 (NHTSA Test No 9332)

This test involves a 2015 Chevrolet Malibu four-door sedan impacted into a flat rigid barrier at 35 mph (56 kph). Figure 3 shows the film kinematics sequence of the right rear 5th ATD that demonstrates no occurrence of submarining. Figure 4 and 5 show the lap and shoulder belt plots. Figure 6 and 7 shows the right and left ASIS Force plots.



Figure 3. ATD kinematics with no submarining.

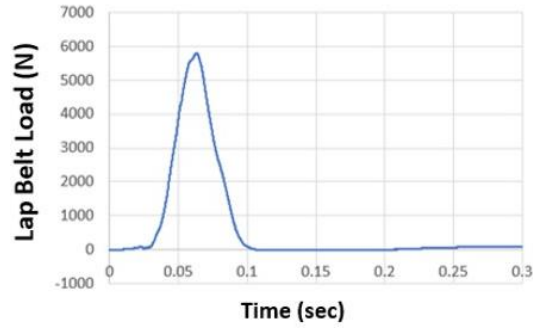


Figure 4. Lap belt load.

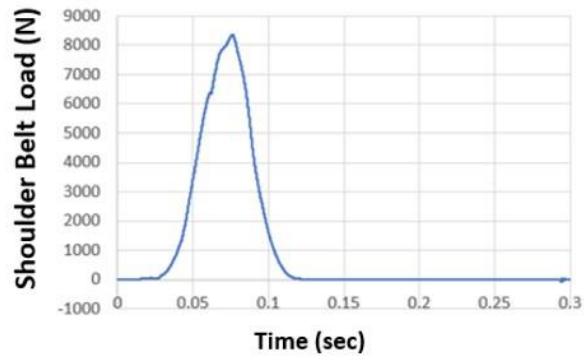


Figure 5. Shoulder belt load.

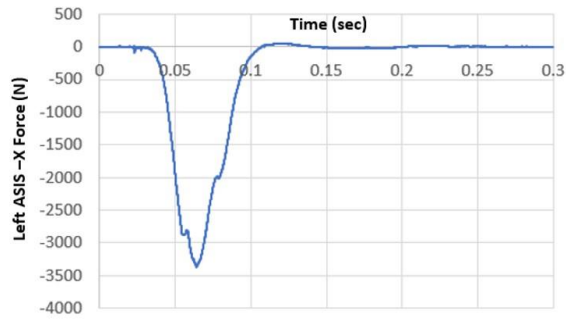


Figure 6. Left ASIS load.

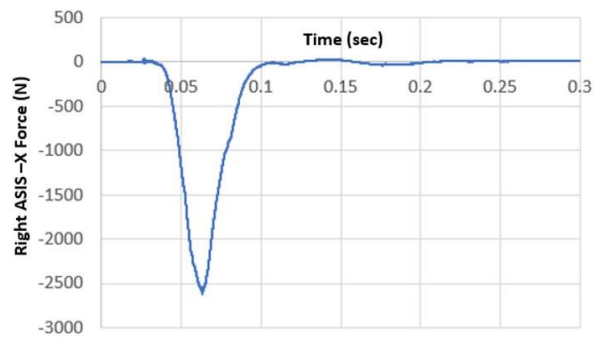


Figure 7. Right ASIS load.

Test-2 (NHTSA Test No 9336)

This test involves a 2015 Mazda 3 four-door hatchback sedan impacted into a flat rigid barrier at 35 mph (56 kph). Figure 8 shows the film kinematics sequence of the right rear 5th ATD that demonstrates no occurrence of submarining. Figure 9 and 10 show the lap and shoulder belt plots. Figure 11 and 12 shows the right and left ASIS Force plots.



Figure 8. ATD kinematics with submarining.

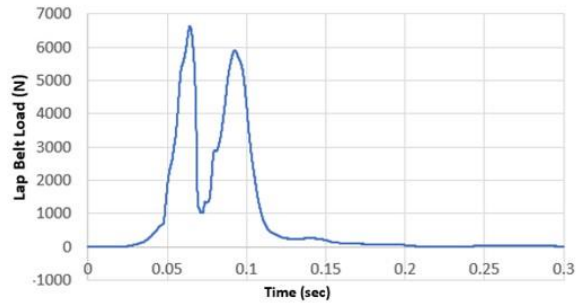


Figure 9. Lap belt load for Mazda 3 test.

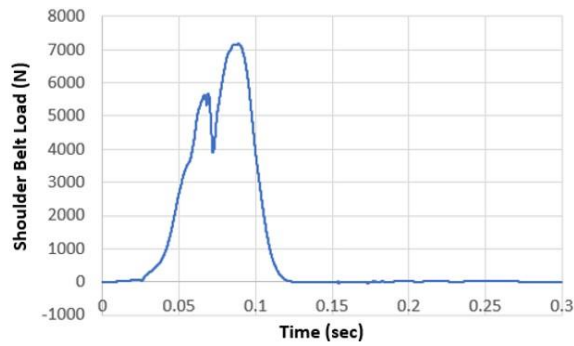


Figure 10. Shoulder belt load for Mazda 3 test.

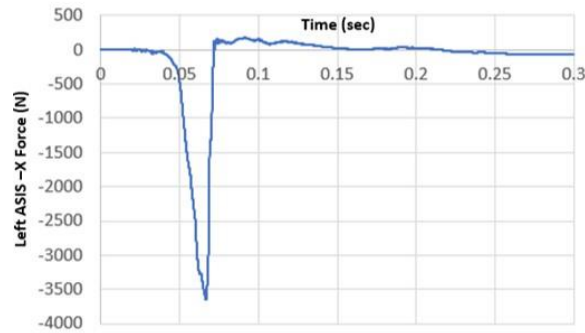


Figure 11. Left ASIS load for Mazda 3 test.

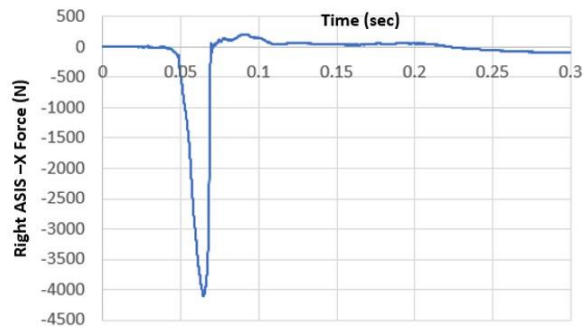


Figure 12. Right ASIS load for Mazda 3 test.

NHTSA TEST COMPARISON

Film Analysis

The film comparison for the ATD kinematics analysis indicates submarining in Test 9336 with 2015 Mazda 3 producing unfavorable ATD kinematics. Test 9332 with 2015 Chevy Malibu shows the favorable occupant kinematics with no submarining of the ATD. The film analysis shows the lap belt kinematics with respect to the ATD pelvis. In the case with submarining, the pelvis rotates backward while moving forward allowing the lap belt to slip from the ASIS zone and migrate upwards and into the abdomen. However, in case of no submarining scenario, the backward pelvis rotation is prevented causing the lap belt to firmly hold on to the ASIS zone during its forward excursion. Figure 13 shows the still image from the film analysis of the Mazda test highlighting the lap belt into the abdominal cavity during the forward excursion of the pelvis. The image also shows the upper torso recline with shoulder point (S-point) lagging behind the H-point. Figure 14 shows the still image from the Chevrolet test highlighting the lap belt on the pelvis during the forward excursion of the pelvis. The image also shows that the shoulder point is not lagging the H-point.

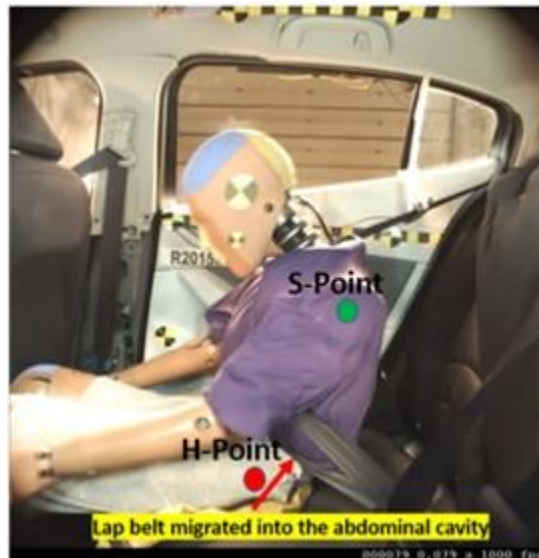

Figure 13. Unfavorable kinematics with submarining.

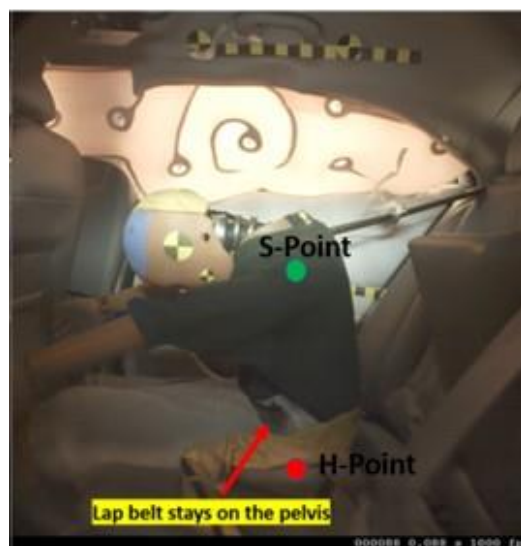


Figure 14. Favorable occupant kinematics without submarining.

Seat Belt Load Analysis

The seat belt load profile, with and without submarining, shows a clear difference. Figure 9 shows the lap belt profile with submarining and Figure 4 without submarining. The belt load profile with submarining always shows a classic hump as visible in Figure 9. This load profile occurs when the pelvis is allowed to rotate backward during its forward excursion on the seat. The backward rotation causes the lap belt to slip from the pelvis causing the drop in the lap belt load. However, the load starts rising once the belt again engages with the abdomen during the ATD's forward excursion. This pelvis rotation kinematics produce the double hump belt load profile. The single loop nature of the belt with the free belt transfer at the latch plate also affects the shoulder belt load profile and demonstrates the hump as shown in Figure 10.

A.S.I.S Load Analysis

The Hybrid III 5th pelvis is equipped with an A.S.I.S load cell capable to measure the belt load and the moment on the pelvis. Figure 15 shows the location of the A.S.I.S load cell on the pelvis of the hybrid 5th ATD.

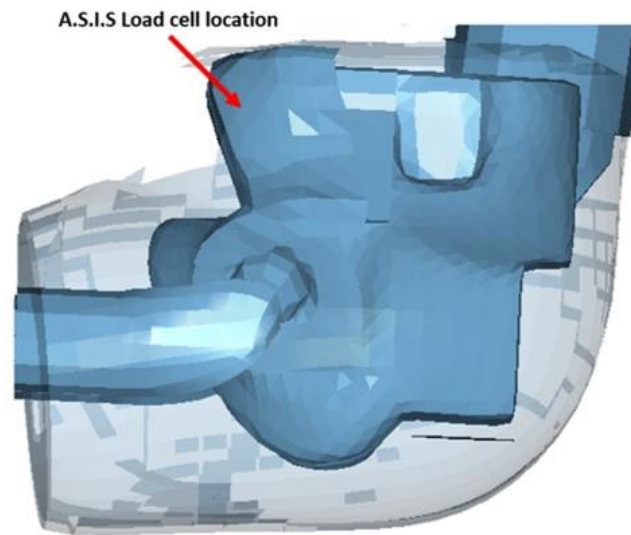


Figure 15. Location of A.S.I.S load cell on the pelvis to measure belt load on the pelvis.

Both tests measured the A.S.I.S loads and moments. In case of submarining, the lap belt slips off from the pelvis producing a sudden drop of the load on the pelvis. Figure 11 and 12 shows the sudden load drop at the right and left A.S.I.S. load cell. With no submarining, the load gradually drops until the ATD starts its rebound as shown in Figure 6 and 7.

REAL WORLD FRONTAL CRASH AND SUBMARINING

In a real-world frontal crash, the occupant's injury pattern in conjunction with a detailed analysis of all other factors provides crucial insight regarding the occupant's motion and injury-producing cause. The subcutaneous fat stranding an increase in its density due to the seatbelt loading can manifest increased attenuation on the CT scan [13,14,15]. The traumatic seatbelt fat stranding observations using CT scan facilitate over-all injury mechanism analysis.

Case Report-1

A 42-year-old female passenger in a right front seat in a mid-size four-door sedan, who was wearing her seatbelt, was involved in a left frontal offset crash. The vehicle EDR data showed 33 mph longitudinal delta V and 11 mph lateral delta-V towards the driver side. She was 5ft 4 inches (164cm) tall and weighed 169 lb (76 kg) at the time of the crash. She sustained head and neck injuries including cervical neck fractures and disruption of posterior ligaments and complex at C1-C2 level with spinal cord injury. Her injury at the C1-2 level is classified as flexion-distraction type injury. She also sustained multiple abdominal injuries including mesenteric defects at mid and distal ileum, 1cm

perforation on the lateral border of the cecum and a large right lower abdominal wall traumatic hernia. She also sustained severe bilateral lower lobe atelectasis. Her overall injury pattern and severity was consistent with her submarining on the right front seat. Her CT scan review demonstrated fat-stranding at the hips and the final lap belt position on the abdomen. Figure 16 shows the subcutaneous fat stranding at the A.S.I.S level on the axial CT. Figure 17 shows the corresponding display of fat stranding on the coronal view. Figure 18 shows the fat-stranding at the final displaced position of the lap belt. The lap belt total displacement on the abdomen was 5.2 inches consistent with the marks on the CT scan and her abdominal injuries. Figure 19 shows the schematics of the initial and final belt position with respect to her abdominal injuries. Her submarining produced unfavorable kinematics causing her neck interaction with the shoulder belt producing flexion-distraction injuries at the C1-C2 level.

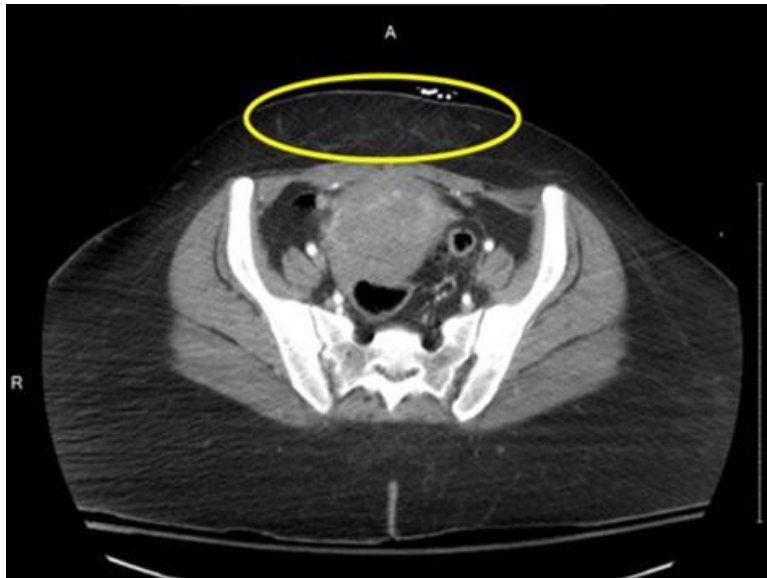

Figure 16. Axial CT at slightly below A.S.I.S level.

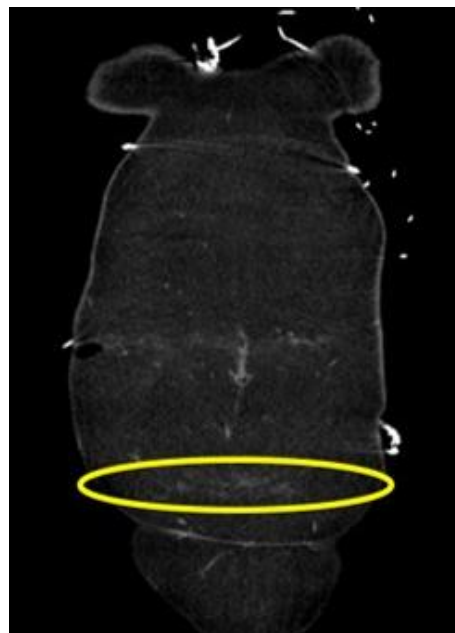


Figure 17. Coronal view of the fat stranding marks at the A.S.I.S level.

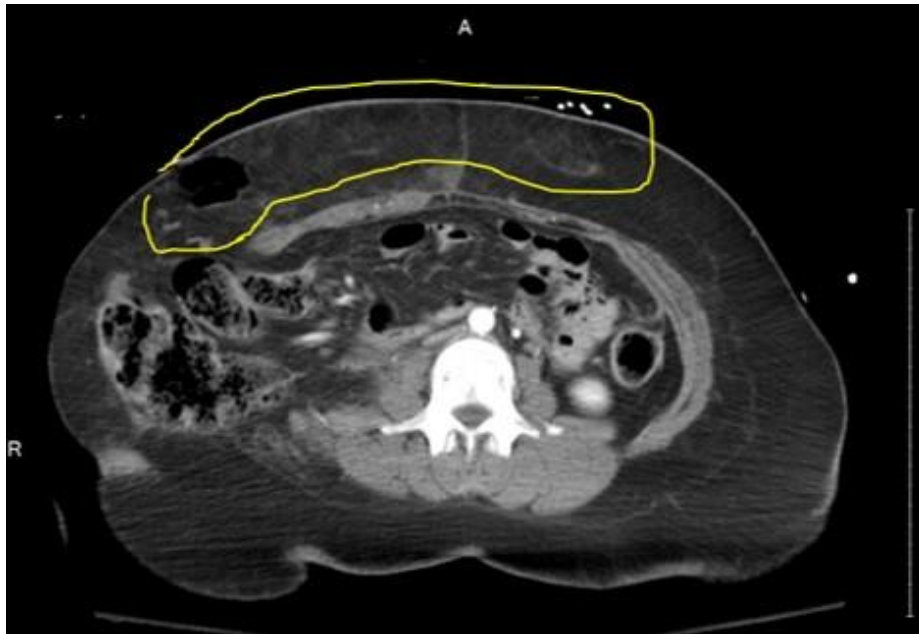


Figure 18. Axial CT at the level of L2-L3 with prominent fat stranding abdominal injuries.

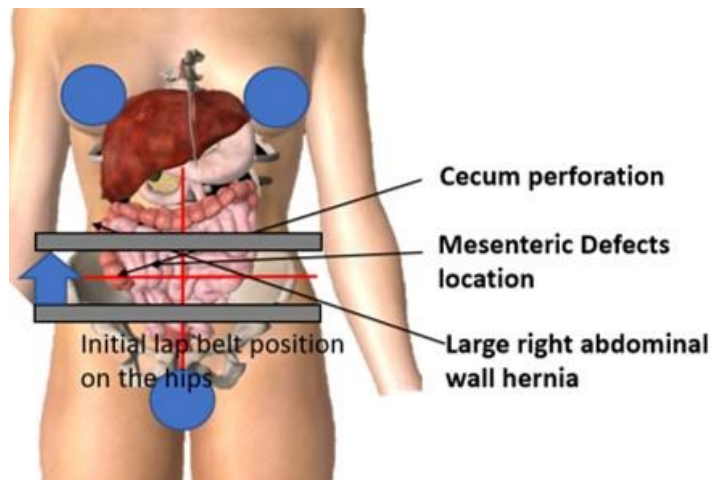


Figure 19. Schematics of the belt movement and abdominal injuries.

Case Report-2

An 11-year-old female passenger in the second row right seat, who had her seatback reclined to approx. 58-60 deg with the vertical, was sleeping with her back on the seatback. She was a properly belted occupant. However, the seatback recline caused her shoulder belt positioned away from her upper torso as the D-ring in this vehicle is mounted on the B-pillar. The frontal crash caused the vehicle to experience a longitudinal change in velocity of 20mph with a minor lateral change in velocity. The seatback recline at the time of crash caused her to submarine under the lap belt. Her acute injury pattern involved clavicle fracture, chance fracture at L2-L3 level in association with several abdominal injuries. She also sustained upper and lower extremity fractures along with facial fractures. Figure 20 shows the axial CT at the level of the chance fracture demonstrating prominent traumatic fat stranding in the anterior abdomen.

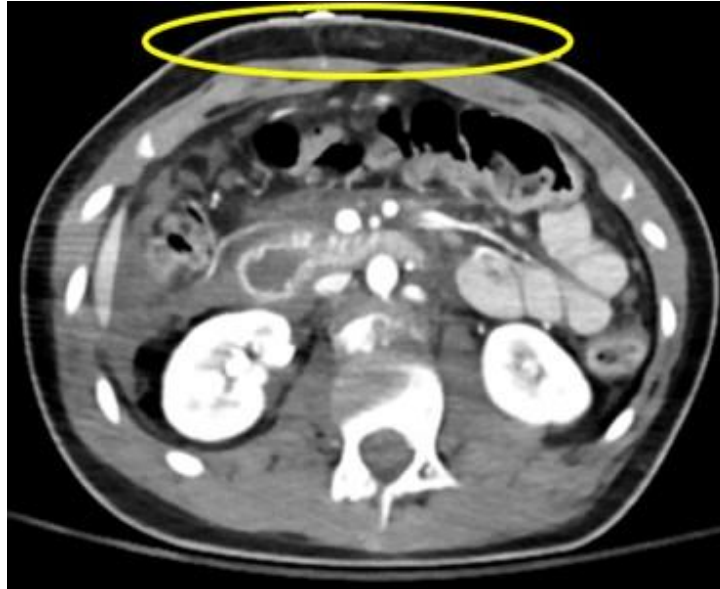

Figure 20. Fat stranding at the level of chance fracture.

Figure 21 shows the axial CT at the level of A.S.I.S of the child occupant that shows the fat-stranding. The increase in the fat density at this level confirms the traumatic contact between the belt and the pelvis. However, due to her reclined position, the pelvis failed to hook the A.S.I.S firmly to prevent her slipping under the lap belt. Figure 22 shows the zoomed anterior portion between the left and right A.S.I.S. Figure 23 shows the schematics of lap belt travel on her body.

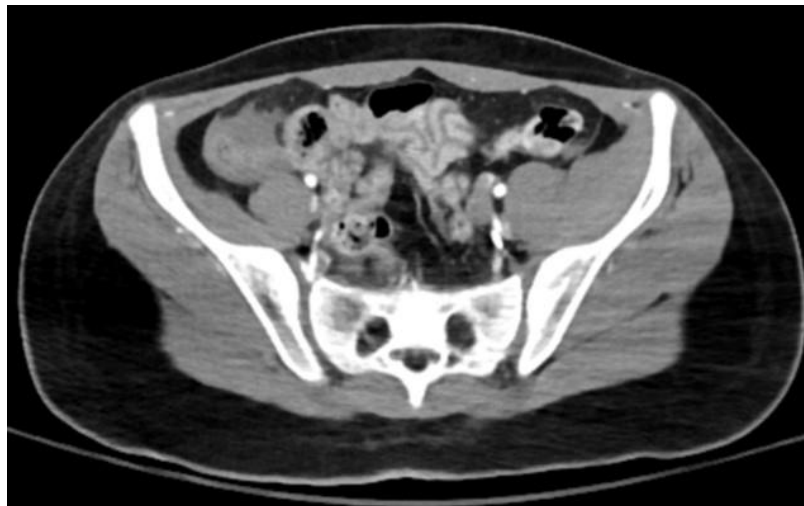

Figure 21. Fat stranding at the level of A.S.I.S

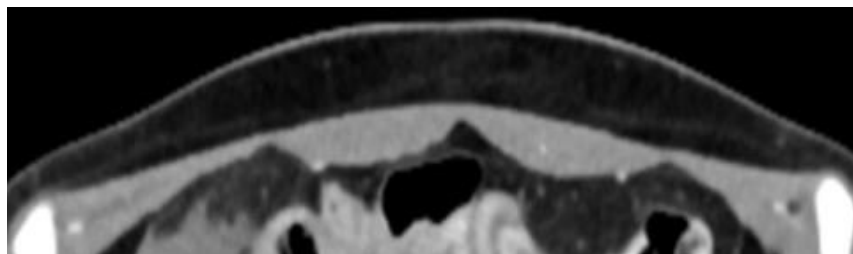


Figure 22. Zoomed image at the level of A.S.I.S demonstrating fat stranding in the subcutaneous fat.

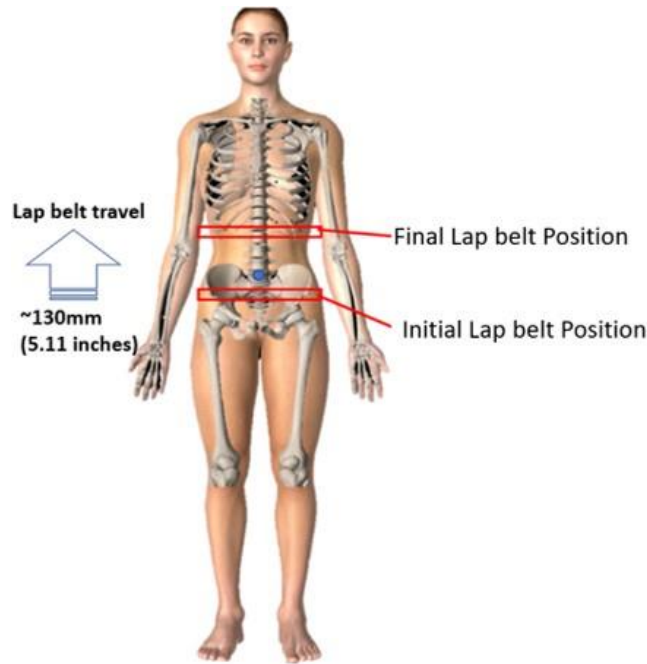


Figure 23. Lap belt displacement from the pelvis to upper abdomen during the crash.

CONCLUSIONS

Occupant submarining in a frontal crash scenario is explained using standard regulatory test data and video. The paper discusses the submarining detection techniques using the film, seatbelt data, and A.S.I.S data. The belt data shows a classic double hump characteristic in the presence of the pelvis backward rotation during its forward excursion on the seat. The film and data analysis show that preventing the backward pelvis rotation during its forward excursion produces overall favorable occupant kinematics by preventing the occupant submarining. This paper shows how the increased attenuation in the subcutaneous fat, below the skin (Camper's fascia) manifest on the CT scan when the belt exerts the compressive and shear loading on the body. Traumatic fat-stranding analysis can be successfully employed in injury causation analysis in conjunction with other available information and data. Seatbelt use, its initial and final position can be determined using the fat stranding analysis.

REFERENCES

- [1] Adomeit, Dieter. Evaluation methods for the biomechanical *quality of restraint systems during frontal impact*. No. 770936. SAE Technical Paper, 1977.
- [2] Adomeit, D. "SEAT DESIGN-A SIGNIFICANT FACTOR FOR SAFETY BELT EFFECTIVENESS. IN: SEAT BELTS: THE DEVELOPMENT OF AN ESSENTIAL SAFETY FEATURE." In Paper No. 791004, presented at the 23rd Stapp Car Crash Conference, San Diego, CA, October 1979. 2003.
- [3] Foret-Bruno, Jean-Yves, et al. "Comparison of Thoracic Injury Risk in Frontal Car Crashes for Occupant Restrained without Belt Load Limiters and Those Restrained with 6 kN and 4 kN Belt Load Limiters." *Stapp car crash journal* 45 (2001): 205-224.
- [4] Adomeit, Dieter, and Alfred Heger. Motion sequence criteria and design proposals for restraint devices in order to avoid unfavorable biomechanic conditions and submarining. No. 751146. SAE Technical Paper, 1975.
- [5] Håland, Yngve. "The evolution of the three point seat belt from yesterday to tomorrow." In *IRCOBI Conference, Madrid*. 2006.

- [6] Thorbole, Chandrashekhar K. "Seatbelt submarining injury and its prevention countermeasures: How a cantilever seat pan structure exacerbate submarining." *Journal of family medicine and primary care* 4.4 (2015): 587.
- [7] Elhagediab, Ali M., and Stephen W. Rouhana. "Patterns of abdominal injury in frontal automotive crashes." In *16 th International ESV Conference Proceedings*, pp. 327-337. 1998.
- [8] Leung, Y. C., C. Tarriere, D. Lestrelin, C. Got, F. Guillon, Manish M. Patel, and Jacques Hureau. "Submarining injuries of 3-point belted occupants in frontal collisions-description, mechanisms and protection." In *Proceedings: Stapp Car Crash Conference*, vol. 26, pp. 173-205. Society of Automotive Engineers SAE, 1982.
- [9] Luet, Carole, Xavier Trosseille, Pascal Drazétic, Pascal Potier, and Guy Vallancien. *Kinematics and Dynamics of the Pelvis in the Process of Submarining using PMHS Sled Tests*. No. 2012-22-0011. SAE Technical Paper, 2012.
- [10] Couturier, Stéphane, Jacques Faure, Ricardo Satué, Joaquim Huguet, and Julien Hordonneau. "Procedure to assess submarining in frontal impact." In *20th International Technical Conference on the Enhanced Safety of Vehicles (ESV) National Highway Traffic Safety Administration*, no. 07-0481. 2007.
- [11] Uriot, Jerome, Pascal Baudrit, Pascal Potier, Xavier Trosseille, Philippe Petit, Hervé Guillemot, Laurent Guérin, and Guy Vallancien. *Investigations on the belt-to-pelvis interaction in case of submarining*. No. 2006-22-0003. SAE Technical Paper, 2006.
- [12] <https://www-nrd.nhtsa.dot.gov/database/VSR/veh/QueryTest.aspx>
- [13] Hartka, Thomas, G. Poplin, Kenadeed Hersi, Abigail Booker, and M. Sochor. "Comparison of Visual and CT 3D Reconstructed Abdominal Seatbelt Sign Locations." *TRAFFIC INJURY PREVENTION* 15 (2014): S247-S249.
- [14] Hartka, Thomas, 2013 CIREN Presentations " Determination of Seat Belt Use and Positioning with Three-Dimensional CT Fat Volume Rendering in CIREN Frontal Crash Case" [https://one.nhtsa.gov/Research/Crash-Injury-Research-\(CIREN\)/2013-CIREN-Presentations](https://one.nhtsa.gov/Research/Crash-Injury-Research-(CIREN)/2013-CIREN-Presentations)
- [15] Thorbole, Chandrashekhar." Traumatic Seat Belt Abdominal Fat Stranding Diagnosis on the CT Scan as a Potential Tool for Injury Causation Analysis" Technical Reference Bulletin 2017, Symposium on International Automotive Technology 2017, Pune, INDIA.